

ARTICLE INFORMATION

Received: February, 27, 2024

Revised: April, 27, 2024

Available online: April, 28, 2024

at : <https://ejournal.malahayati.ac.id/index.php/minh>

Effectiveness of the healing rate of sickle wounds with *musa acuminata colla genome AA* extract gel on *rattus novergicus*

Auliya Wanda Azzarin, Sugeng Mashudi*, Sulistyo Andarmoyo, Fadhilah Nurul Karimah, Nuraini Khoirotun Amanah

Fakultas Ilmu Kesehatan Universitas Muhammadiyah Ponorogo

Corresponding author: *E-mail: sugengmashudi@umpo.ac.id

Abstract

Background: Wounds occur due to the damage of the body's network caused by several factors. To prevent severe bleeding or complications, it requires treatment that can assist in the healing process. One of the treatments is the use of natural substances containing flavonoids. Flavonoids can be naturally found in plants, one of which is in *Musa Acuminata Colla genom AA*. The gel preparation of *Musa Acuminata Colla genom AA* extract has the advantage of easy application, practicality, and maintaining skin hydration.

Purpose: To determine the effect of *Musa Acuminata Colla genom AA* content on the speed of healing incision wounds.

Method: Experimental with completely randomized design. *Musa Acuminata Colla genome AA* extract was processed through maceration with 70% ethanol. The formula contains methyl paraben, propyl paraben, propylene glycol, HPMC with varying concentrations: F1 (10%), F2 (20%), and F3 (40%). Evaluation of the physical properties of the preparation includes organoleptic examination, drying time, macroscopic examination, and data analysis using Welch One Way ANOVA and Howell's Post Hoc Games.

Results: The results of the Welch One Way ANOVA showed that the experimental group had a significant effect on days 3, 5, and 7 after injury. The results of the Howell Post Hoc Games showed a significant difference between the control and experimental groups on the same day.

Conclusion: *Musa Acuminata Colla Extract AA genome 40%* has the effect of increasing the re-epithelialization process on wound healing, and its effectiveness is almost equivalent to Loematuell branded wound care tools.

Keyword: Incision Wounds; *Musa Acuminata Colla Genom AA*; Wound Healing Speed.

INTRODUCTION

The skin is an organ that protects the body's surface, regulates body temperature, and controls water levels in the body. The skin's structure consists of a layer of the epidermis (cuticula) and the dermis (korium). On the part of the skin, there are sweat glands that penetrate the skin and accompany the hair. On the corium or dermis, it is composed of fibrous tissue and elastic connective tissue, and on the surface of the Dermis there are small papilles that contain branches of capillary blood vessels. So when there is an opening on the surface of the skin, it will

cause bleeding. To cope with bleeding on the skin requires proper treatment (Pearch, 2011; Linder 2020; Gilaberte, Prieto-Torres, Pastushenko, & Juarranz, 2016).

The incidence of skin injuries since the first year of Covid-19 was higher than in the previous year, 17.9% (1092/6090) compared to 15% (887/5906), with a significant increase in the months with the highest incidence (Nieto-García, Carpio-Pérez, Moreiro-Barroso, Rubio-Gil, Ruiz-Antúnez, Nieto-García, & Alonso-Sardón, 2023). Traditional medicine is now

becoming more popular and frequently used by society. This is due to some of the advantages that are considered by its users, such as the more affordable price, the availability of abundant ingredients in the surrounding environment, as well as the benefits obtained from the content of traditional medicine in accordance with the needs of the community. In addition, the attractive side of the material is that it uses natural ingredients, so the risk of side effects from the use of the drug is relatively small. Nevertheless, with regard to the information surrounding traditional medicine that plays a role in helping recover from disease, further research on medicinal plants is needed to be as beneficial as possible to society (Tamuntuan, De Queljoe, & Datu, 2021).

In Indonesia, there are various kinds of medicinal plants. One of them is the *Musa Acuminata Colla genome AA* (*Musa paradisiaca*) (Kritsi, Tsiaka, Sotiroudis, Mouka, Aouant, Ladika, & Sinanoglou, 2023). In addition to its easy presence in the surrounding environment, its overall usefulness in helping to cope with some health problems can be used as an advantage, the potential of a variety of bioactive compounds that can collate in health recovery. For example, in helping wound healing processes. Inside the discharge section of *Musa Acuminata Colla genome AA* contains flavonoids that act as anti-inflammatory. The wounds occurred as a result of the loss of tissue in the body due to a number of events that damaged the structure of the tissue such as sharp and blurred trauma, temperature changes, chemicals, burns, scratches, electric shocks, even animal bites. The situation has influenced the prevalence of large numbers of diseases worldwide so enforcement is necessary to facilitate normal recovery effectively and accelerate recovery (Budi, Anitasari, Ulfa, Juliastuti, Aljunaid, Ramadan, & Shen, 2022; Turay, 2023).

The wound healing occurs gradually, starting with inflammation, polypheration, and regeneration (Hu, Guo, Hu, & Sun, 2020; Majewski, 2006; Primadina, Basori, & Perdanakusuma, 2019). In general, wound healing occurs through four stages: hemostatic, inflammatory, proliferation, and remodelling. The phases must occur in an accurate sequence and at a certain time, and within an indefinite period of time, depending on the type, depth, width, treatment, and pattern of wound treatment (Falbo, Spizzirri,

Restuccia, & Aiello, 2023). When the skin gets wounded, the body will respond with the occurrence of a complex biological activity. Starting with a narrowing of small blood vessels and capillaries around the wound area aimed at reducing local blood flow, then thrombocytes will accumulate into frozen blood, followed by an inflammatory response characterized by increased permeability and activation of inflammation cells to initiate and regulate wound healing, then a process of maturation and reconstruction of new tissue that can last long, months to years (Huang, Dong, Zhao, Lu, Huang, Yuan, & Qian, 2022).

One wound execution is the use of complementary therapy followed by proper wound treatment procedures. In his research, he combined chitosan and chondroitin sulfate to synthesize hydrogel through frozen gelation processes and enrich it with garlic (Gar). So it can be concluded that the antibacterial effects obtained from natural ingredients are beneficial to help wound healing and tissue regeneration (Masood, Makhdoom, Channa, Gilani, Khan, Hussain, & Rehman, 2022).

Wound treatment can be done by various methods. The most common method is to use a 0.9% NaCl liquid which belongs to an isotonic solution that is anti-irritant, protects tissue granulation processes from dry conditions, as well as a sins moisture in the area around the wound (Purnamasari, 2021). Besides, there are tools made of chemicals combined with a sterile cashier that is now available under various trademarks. However, among some of the methods that have been mentioned, there is a more effective method, the hydrogel wrapping which is mechanical so compatible with the structure of biological tissue and the remarkable absorption of water storage so superior in wound moisture and continuously absorbing exudate. Then, a tissue-shaped hydrogel structure with three-dimensional pores almost identical to the natural ECM which facilitates cell reproduction and migration. So looking at the various advantages of the hydrogel, on this occasion, the researchers wanted to mix extract of the *Musa Acuminata Colla stem* with the AA genomes as a medium which will be a drug that helps in the process of wound healing. The hydrogel's mechanical properties, if assumed, are not likely to interfere with comfort during the wound treatment process. The researchers are enthusiastic about this production

Auliya Wanda Azzarin, Sugeng Mashudi*, Sulisty Andarmoyo, Fadhilah Nurul Karimah, Nuraini Khoirotun Amanah

Fakultas Ilmu Kesehatan Universitas Muhammadiyah Ponorogo
Corresponding author: *E-mail: sugengmashudi@umpo.ac.id

DOI: <https://doi.org/10.33024/minh.v7i2.227>

because no other research has discussed this innovation, namely the formulation of the hydrogel + extract of the stem of the *Musa Acuminata Colla genome AA*. Some of these theories are in line with the purpose of this research, which wants to know the effectiveness of the contents of the AA genome in helping wound healing by testing comparisons between concentrations and comparing them with tools commonly used in chemical-based wound treatment.

RESEARCH METHOD

The study was conducted in the laboratory of the Sunan Giri Ponorogo Institute of Pharmaceutical Studies for the period November 2023. This type of research is a laboratory experimental study of the Complete Random Design, the test animals are grouped into 2 groups, i.e. the control group (negative and positive) with each group of 1 mouse and the treatment group (concentration 10%, 20%, and 40%) with each concentration of 3 mice. The tools and materials used for some different stages. The stages undertaken to carry out this research range from the preparation stage of the gel preparation to the pre-clinical trial stage.

Stage of making gel *Musa Acuminata Colla genom AA*; The sample used is a stem of the *Musa Acuminata Colla genome* taken from the village of Mlilir, Dolopo District, Madiun District, East Java Province. Using tools; knife, sieve, blender, black cloth cover, tray, airtight jar, basin, thin cloth, beaker glass 500ml, digital scale, pot, basin, stirring spoon and gas stove. The materials used are; alcohol 70%, *Musa acuminata colla genome AA*, HPMC, propylene glycol, methylparaben, propylparaben and aquades.

Preparation of simplisia; *Musa acuminata Colla the AA genome* was taken and first cut into small pieces with the aim of facilitating the drying process. Then washed to clean and placed in a peeled and wide container and then sunbed with a black cloth cover for 5 x 24 hours. Sun exposure using black

fabric is intended to keep the flavonoid content of the discharge from being damaged by direct sunlight. Because flavonoids are sensitive to light and heat, they can degrade due to the breakdown of the molecular chain and affect the occurrence of oxidation reactions so that other compounds can evaporate quickly (Ariani, Musiam, Niah, & Febrianti, 2022). When the leak has dried up, the next step is smoothing. The dry flakes are smoothed using a blender and then mixed to take a soft portion without fiber.

Maceration proses; Maceration is commonly referred to as a cold extraction that aims to extract the chemical content found in the simplisia. The technique is to soak the simplisia with a solvent. The contents of flavonoids can be dissolved with ethanol (Haryanti, Larasati, & Agusta, 2021). In this study, simplisia *Musa acuminata colla genome AA* weighing 100.11 grams was soaked using 70% alcohol as much as 1000ml then mixed. The maceration process lasted for 3 x 24 hours and was inhabited. Once the maceration process is completed, the simplisia soaked with the alcohol will appear to stick to the bottom part of the cup so it needs to be mixed first and then poured on a thin fabric to perform filtration under which a Bascom has been prepared to accommodate the observation. The next step is the evaporation process aimed at separating the active compounds contained in the *Musa acuminata colla genome AA* from the solvent. We did it with the help of a stove. So the basin containing the Maserati water is put in a large boiling pot and then infused without covering for an hour until thickened.

Filtration proses; When the evaporation/measurement process is completed, there is an extract clamping. The extract weighs 13.71 grams. Then the next step is to mix the extract with a HPMC gel that already contains methylparaben and propylenglycol that acts as an anti fungus. The preparation is divided into three concentrations of 10%, 20% and 40%.

Auliya Wanda Azzarin, Sugeng Mashudi*, Sulisty Andarmoyo, Fadhilah Nurul Karimah, Nuraini Khoirotn Amanah

Fakultas Ilmu Kesehatan Universitas Muhammadiyah Ponorogo
Corresponding author: *E-mail: sugengmashudi@umpo.ac.id

DOI: <https://doi.org/10.33024/minh.v7i2.227>

Table 1. Composition of the *Musa acuminata colla genome AA* gel preparation

Materials	F1 (10%) gr	F2 (20%) gr	F3 (40%) gr
Ekstrakt of <i>Musa acuminata colla genom AA</i>	1 gr	2 gr	4 gr
HPMC	1.5 gr	1.5 gr	1.5 gr
Metylparaben	0.4 gr	0.4 gr	0.4 gr
Propylparaben	0.4 gr	0.4 gr	0.4 gr
Propilenglikol	5 gr	5 gr	5 gr
Aquades	100 ml	100 ml	100 ml

Information: F1 ekstrakt MACG 10%, F2 ekstrakt MACG 20%, dan F3 ekstrakt MACG 40%.

Pre-clinical testing; The experiment used a male white rat (*Rattus norvegicus*) as a test animal that had been adapted for about a week and was divided into two groups: the control group (positive and negative) and the treatment group which was still divided again into three subgroups based on the concentration of three mice in each concentration. The positive control group used wound treatment tools with Loematuell branded chemicals and negative controls using a gel-based HPMC. The total of male white mice used was 15 with a weight of 200 grams each. Mice aged 6-9 months are best suited to study osteoporosis due to stable bone replacement rates; however, rats aged under 6 months or over 9 months are not ideal due to high bone growth rates and aging processes. In our study, the mice used were 6 months old (Ghasemi, Jeddi, & Kashfi, 2021). Using tools; surgical knife, stirring rod, anatomic tweezers, surgical tweezers, bandage scissors, ruler, hair clipper, surgical tape, hydrophilic gauze, alcohol swab, depressor, rat cage, mouse, curved needle, care assessment logbook, bottles and feeding containers, broomstick, trash bin, cotton, and instrument tray. The materials used are; Chloroform Ether, gel Formulation of *Musa Acuminata Colla Genom AA* with concentrations of 10%, 20%, and 40%, Sodium Chloride (NaCl), white rats weighing 200 grams, a total of 15 rats, Rat Feed (HI-PRO-VITE A591K), water, fine husk and coarse husk.

To maintain the stability of the condition of the test animal, good care is required. In animal care, researchers focus on food, drinks, and cages. Test animals fed with Hi – Pro – Vit produced by PT. Charoen Pokphand Indonesia, TBK. In a day feeding is given 1x in the afternoon (about 2 p.m.) with 50 grams of water per cage and a drink of 140 ml of clean water each cage. Food is deliberately given not too much to keep the rat's weight stable. Cleaning the

cage is done every three days by replacing the dirt that's been dirty. The patches need to be replaced because they are already mixed with mouse urine and poop so that when not routinely replaced can trigger the growth of bacteria or germs that will affect the health of rats especially in the process of clinical trials.

The test animals were then shaved and shaved 2 cm long, 1 mm deep, and 1 mm wide. The comparison of the healing process between the dosage types is judged by the speed of healing. His score criteria were faster than Loematuell, compared to Loematoell, and slower than Loamatuell. The timeframe the researchers use for treatment is 7 days with a duration of treatment of 2 days once, rationally so as not to interfere with the stage of wound healing. The dose given in one treatment is 2 ml of stirring rod. Treatment is done at the same time as feeding. To determine the progress of the wound healing process, the instruments used by the researchers are a grid to observe the lengths of wound size and a logbook for reviewed macroscopic assessment of erythema and skin swelling. In this study, the wound is said to heal to the stage of proliferation in which there is a healing process that starts from the formation of new capillaries to the creation of a new epithelium on the surface of a wound (Ministry of Health of the Republic of Indonesia, 2022).

To monitor the progress of the wound healing process, the instruments used by the researchers included a ruler to observe the length of the wound and a logbook for macroscopic assessments, focusing on erythema and skin swelling. In this study, a wound was considered healed when it reached the proliferation stage, which involves the healing process starting from the formation of new capillaries to the development of new epithelium on the wound surface (Ministry of Health of the Republic of Indonesia, 2022).

Auliya Wanda Azzarin, Sugeng Mashudi*, Sulisty Andarmoyo, Fadhilah Nurul Karimah, Nuraini Khoiroton Amanah

Fakultas Ilmu Kesehatan Universitas Muhammadiyah Ponorogo
Corresponding author: *E-mail: sugengmashudi@umpo.ac.id

DOI: <https://doi.org/10.33024/minh.v7i2.227>

Effectiveness of the healing rate of sickle wounds with *musa acuminata colla genome AA* extract gel on *rattus novergicus*

Observations were carried out by monitoring the ratio of wound healing rates between the control group and the treatment group. Parameters of macroscopic assessment by seeing the presence of the redness phase until the wound begins to close. Then to measure the length of the wound measured with a scissor.

The organoleptic test is a test of a substance/product using human senses. The sensory instruments used in this study are the sense of sight (eye), sense of smell (nose), and sense of perception (hand). The function of this test is to evaluate the product according to the sensors and stimuli received by the senses. Assessment involves the ability to

detect, recognize, differentiate, compare shapes/textures, colors, and scents.

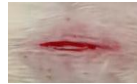



















Furthermore, to determine the effectiveness of wound healing with the administration of the preparation of *Musa acuminata* gel *Colla genome AA* in white rats was evaluated with 2 aspects. First, macroscopic observations were performed to observe differences in the healing rate of the cut wound between five groups with different drug concentrations given. Observation for the condition of the scratch wound was observed from the presence of redness until the wound closed (Re-epitelisasi). The result was analyzed using the Welch ANOVA and Post Hoc Games Howell, SPSS 25 tests.

RESEARCH RESULTS

Table 2. The Results of The Organoleptic Test On MACG Gel

Parameter	Basis (HPMC)	F1 (10%)	F2 (20%)	F3 (40%)
Texture	Fluid, thick, homogen	Fluid, thick, homogen	Fluid, thick, homogen	Fluid, thick, homogen
Fragrance	Odorless	Sweet	Sweet	Sweet
Color	Clear	Light yellowish brown	Light yellowish brown	Light yellowish brown

Table 3. Results of Wound Healing Observations (7 Days)

	Day 1	Day 3	Day 5	Day 7
F1				
F2				
F3				
K+				
K-				

Auliya Wanda Azzarin, Sugeng Mashudi*, Sulisty Andarmoyo, Fadhilah Nurul Karimah, Nuraini Khoirotn Amanah

Fakultas Ilmu Kesehatan Universitas Muhammadiyah Ponorogo
 Corresponding author: *E-mail: sugengmashudi@umpo.ac.id

DOI: <https://doi.org/10.33024/minh.v7i2.227>

Table 4. Observation Results for Erythema (Redness)

Rats	Score within 7 days (4x treatment)				
	F1	F2	F3	K+	K-
1	13	10	11	8	15
2	12	14	8	8	13
3	13	12	9	8	15
Mean	12,6	12	9,3	8	14,3

Description: F1 (MACG 10%), F2 (MACG 20%), F3 (MACG 40%), K+ (Control Positif), K- (Control negatif). Score 0 (no erythema), +1 (slight erythema/almost invisible), +2 (erythema is obvious), +3 (moderate to strong erythema), +4 (severe erythema (wounds)). Wounds are said to heal faster if the average number is smaller.

According to the results of the observation, the whole group had redness on the first day but there was a difference in the time when the redness disappeared. The K+ group (positive control) is the fastest group in the disappearance of redness. The longest time was in group K- (Base HPMC) and group F1 (concentration 10%). The averages of the redness were calculated on days 1, 3, 5 and 7. The results showed different averages, but there was a small gap between F3 and positive control.

Result of the Welch One Way ANOVA dan Post Hoc Games Howell test

Table 5. Mean and standart deviation Daily wound healing (within 7 days)

Consentration	Day 1	Day 3	Day 5	Day 7	Sig.
F1 (10%)	1.833 ± 0.2887	1.667±0.2887	1.367 ± 0.2309	0.900 ± 0.1731	0.031
F2 (20%)	1.500 ± 0.3000	1.500 ± 0.3000	1.200 ± 0.1732	1.033 ± 0.0577	0.129
F3 (40%)	1.533 ± 0.1528	1.233 ± 0.1155	1.000 ± 0.1000	0.700 ± 0.1000	0.006
K+	1.533 ± 0.0577	1.067 ± 0.1155	0.500 ± 0.1000	1.000 ± 1.0000	0.001
K-	1.600 ± 0.1000	1.500 ± 0.1000	1.467 ± 0.1155	1.367 ± 0.1155	0.268

The data of the control group and the above experimental group were then tested for normality with the result of normal distributed data ($p > 0.05$) and the test for non-homogeneity ($p < 0.05$). Next, Howell conducted a Post Hoc Games test to see the significant differences in influence between the respective concentrations. The table can be seen as follows:

Table 6. Result of games Howell test

	Consentration	Mean Different	Sig
K-	F1 (10%)	0.1833	0.071
	F2 (20%)	0.2750*	0.001
	F3 (40%)	0.4500*	0.010
	K+ (kimia)	0.6833*	0.012

Information (*) there are significant differences

Howell's Post Hoc Games test results in the table above showed that there was a difference in the number of degrees between each of the significant concentrations ($p < 0.05$) in almost the entire treatment group, except for F1 (concentration of gel supply 10%) with negative control (HPMC) ($p > 0.05$).

Auliya Wanda Azzarin, Sugeng Mashudi*, Sulisty Andarmoyo, Fadhilah Nurul Karimah, Nuraini Khoiroton Amanah

Fakultas Ilmu Kesehatan Universitas Muhammadiyah Ponorogo
Corresponding author: *E-mail: sugengmashudi@umpo.ac.id

DOI: <https://doi.org/10.33024/minh.v7i2.227>

DISCUSSION

Based on the results of the research, the potential preparation of the *Musa acuminata gel Colla genome AA* can be attributed to the flavonoid compounds, tannins, and saponins contained in the banana stems. These three contents work together in the wound healing process with its functions. Flavonoids and saponins act as antibacterial agents that act by affecting the constituent components of peptidoglycans in bacterial cells, as well as stimulating inflammatory-related cells such as lymphocytes, monocytes, natural cell killers, neutrophils, macrophages, and mastocytes (Ananta, 2020). Besides, the flavonoid functions as a hemorrhage inhibitor and decreases the aggression of platelets. The tannins act as an antiseptic and form a protective layer for the related tissue so that it can help the wound closure process (Ministry of Health of the Republic of Indonesia, 2022).

The wound healing process varies depending on the severity, location, and extent of the wound (Ministry of Health of the Republic of Indonesia, 2022).

Inflammatory Phase

In this phase, the injured body undergoes a hemostatic attempt to stop bleeding. Continued constriction of the blood vessels through the process

of platelet aggregation and the formation of fibrin nets to activate a series of blood clotting reactions. Then, a phase of inflammation occurs in which there is a process of bacterial elimination by neutrophils and macrophages accompanied by increased capillary permeability and expansion of blood vessels that function in filling oxygen and nutrients in damaged tissues.

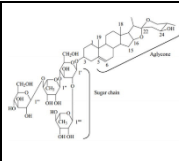
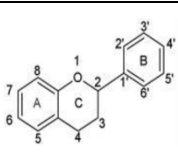
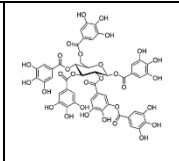
Proliferative Phase

This phase is related to the phase of inflammation in which, at the time of the inflammation, a new capillary formation occurs called angiogenesis. Continues the process of granulation characterized by the formation of red tissue containing capillaries at the base of the wound and eventually forming collagen.

Maturation/Remodeling Phase

This phase can last for years. The process of collagen formation, the absorption of inflammatory cells occurs. The scar tissue that was initially red and thick turned pale and thin. The wound will be scratched to a maximum of about 80%. In general, the *Musa Acuminata Colla genome AA* stem contains various compounds, including flavonoids, tannins, and saponins, which contribute to the wound-healing process.

Table 7. Documentation of flavonoid, tannin, and saponin

		
Saponin	Flavonoid	Tannin

Saponin

Saponins are highly polar compounds with high bioactivity. It also contains anti-inflammatory agents that can help in wound healing. It starts with the occurrence of increased permeability as the surface tension of the cell decreases so that the intracellular part comes out as a result of cell leakage (Ananta, 2020).

Flavonoid

It is composed of a type of polyphenol compound that is polar so it is soluble in solvents such as water, ethanol, butanol, methanol and acetone. In addition, there is anti-inflammatory activity in it which is demonstrated by the presence of flavonoid binding energy in cyclooxygenase cycles of -8.77 kcal/mol to 6.24 kcal / mol which, when compared to the Celecoxib standard (-8.30 kkal/mol) is not much different (Ananta, 2020). These anti-inflammatory

Auliya Wanda Azzarin, Sugeng Mashudi*, Sulisty Andarmoyo, Fadhilah Nurul Karimah, Nuraini Khoirotn Amanah

Fakultas Ilmu Kesehatan Universitas Muhammadiyah Ponorogo
Corresponding author: *E-mail: sugengmashudi@umpo.ac.id

DOI: <https://doi.org/10.33024/minh.v7i2.227>

agents work by producing pro-inflammatory mediators to stimulate cells associated with inflammation, including monocyte lymphocytes, natural killer cells, neutrophils, macrophages, and matocyte cells.

Tannin

Included in the kind of polyphenol compounds of the flavonoid group that have many benefits. It acts as an anti-oxidant and anti-inflammatory agent, serves as a skin tightener, and prevents re-infection by forming a protective layer for the wounded tissue (Ananta, 2020).

The administration of the preparation of the *Musa acuminata Colla genome AA* gel on a cut wound at a dosage of 2 mg has been shown to help the wound healing process. Based on this study, within a week period, the healing of the cut wounds is faster when given the *Musa Acuminata colla gene* gel at a concentration of 40%. This can be seen from the results of observations of erythema which has a ratio of 9.3 where the distance is not too far with the wounds healing on positive control. In addition, the wound also began to close on the 7th day with a slight leakage, so in line with the scale of this study's assessment that the wounds can be said to heal in the proliferation process. In the proliferation process, parallel processes occur: angiogenesis (the process of forming new capillary vessels), re-epithelization, the formation of granulated tissue, and collagen deposition at the site of the wound. So, the wounded skin will be filled with inflammatory cells, fibroblasts, and collagen which will form red tissue, because it contains blood vessels called granular tissue (Ananta, 2020).

After the data was analyzed using the SPSS instrument, the results also showed that there were significant differences between the respective concentration amounts, except at F1 (10%) and K-(gel/HPMC base). Thus the conclusion is that the effect of the administration of *Musa acuminata gel Colla genome AA* (F3) is almost equal to the speed of positive control. This is influenced by wound treatments that are done every two days and the ingredients used are natural, so it takes a little longer than chemicals. In addition, the depth and length of the wound is also a factor in wound healing because in the healing wound can vary. It is worth noting, in general in wound healing has a number of factors that influence the healing process. These factors include

infections, the type of tissue that is traced, the location (the trace tissue's characteristics), the abnormal growth of cells and the production of extra-cellular matrices, and the mechanisms of fibrosis that are basically not very different from the healing of other wounds. Therefore, under similar conditions, the cut wound has the same chance of healing faster by using a gel *Musa acuminata Colla AA* genomic concentration of 40%.

In fact, there have been previous studies on the content of banana stems that have potential in wound healing, such as in a study conducted by Pareda et al., (2022) with the subject of the study of white rats (*Rattus novergicus*), banana rod rubber (*Musa acuminata L.*) capable of accelerating and giving effect on wounds made (cut wounds) by the researchers. But the difference here is the type of banana stick used, the method of processing the contents of the banana, the dosage, the duration of the study, and the frequency of treatment.

CONCLUSION

Based on the results of the study showed that the administration of gel extract *Musa acuminata Colla genome AA* can help accelerate the healing of incision wounds and with a concentration of 40% said to be more effective than 10% and 20%. The limitation in this study is the use of test animals in small quantities so that data analysis uses ($\alpha < 0.05$). Further research is needed to perform phytochemical tests on the *Musa acuminata Colla genome AA* to determine the percentage of compounds that can help wound healing and perform microscopic tests to examine inflammatory cells, collagen, the number of fibroblasts, and the degree of angiogenesis.

REFERENCES

- Ananta, G. P. (2020). Potensi batang pisang (*Musa Pardisiaca L.*) dalam penyembuhan luka bakar. *Jurnal Ilmiah Kesehatan Sandi Husada*, 9(1), 334-340.
- Ariani, N., Musiam, S., Niah, R., & Febrianti, D. R. (2022). Pengaruh Metode Pengeringan Terhadap Kadar Flavonoid Ekstrak Etanolik Kulit Buah Alpukat (*Persea americana Mill.*) dengan Spektrofotometri UV-Vis. *Jurnal Pharmascience*, 9(1), 40-47.

Auliya Wanda Azzarin, Sugeng Mashudi*, Sulisty Andarmoyo, Fadhilah Nurul Karimah, Nuraini Khoiroton Amanah

Fakultas Ilmu Kesehatan Universitas Muhammadiyah Ponorogo
Corresponding author: *E-mail: sugengmashudi@umpo.ac.id

DOI: <https://doi.org/10.33024/minh.v7i2.227>

Effectiveness of the healing rate of sickle wounds with *musa acuminata colla genome AA* extract gel on *rattus norvegicus*

- Budi, H. S., Anitasari, S., Ulfa, N. M., Juliastuti, W. S., Aljunaid, M., Ramadan, D. E., & Shen, Y. K. (2022). Topical medicine potency of *Musa paradisiaca* var. *sapientum* (L.) kuntze as oral gel for wound healing: an in vitro, in vivo study. *European Journal of Dentistry*, 16(04), 848-855.
- Falbo, F., Spizzirri, U. G., Restuccia, D., & Aiello, F. (2023). Natural compounds and biopolymers-based hydrogels join forces to promote wound healing. *Pharmaceutics*, 15(1), 271.
- Ghasemi, A., Jeddi, S., & Kashfi, K. (2021). The laboratory rat: Age and body weight matter. *EXCLI J* 20: 1431–1445.
- Gilaberte, Y., Prieto-Torres, L., Pastushenko, I., & Juarranz, Á. (2016). Anatomy and Function of the Skin. In *Nanoscience in dermatology* (pp. 1-14). Academic Press.
- Haryanti, S., Larasati, R. D., & Agusta, H. (2021). Optimasi Waktu Maserasi dan Konsentrasi Ekstrak daun sirih hijau (*Piper Betle* Linn) dalam pembuatan gel antiseptik kulit. *Jurnal Konversi*, 9(2), 8.
- Hu, J., Guo, S., Hu, H., & Sun, J. (2020). Systematic review of the efficacy of topical haemoglobin therapy for wound healing. *International Wound Journal*, 17(5), 1323-1330.
- Huang, C., Dong, L., Zhao, B., Lu, Y., Huang, S., Yuan, Z., & Qian, W. (2022). Anti-inflammatory hydrogel dressings and skin wound healing. *Clinical and Translational Medicine*, 12(11), e1094.
- Kritsi, E., Tsiaka, T., Sotiroudis, G., Mouka, E., Aouant, K., Ladika, G., & Sinanoglou, V. J. (2023). Potential Health Benefits of Banana Phenolic Content during Ripening by Implementing Analytical and in Silico Techniques. *Life*, 13(2), 332.
- Linder, K. E. (2020). Structure and Function of the Skin. *Feline Dermatology*, 3-21.
- Masood, F., Makhdoom, M. A., Channa, I. A., Gilani, S. J., Khan, A., Hussain, R., & Rehman, M. A. U. (2022). Development and characterization of chitosan and chondroitin sulfate based hydrogels enriched with garlic extract for potential wound healing/skin regeneration applications. *Gels*, 8(10), 676.
- Majewski, M. (2006). Fizjoterapia kobiet z obrzękiem chłonnym kończyny górnej po leczeniu raka sutka. *Physiotherapy/Fizjoterapia*, 14(4).
- Ministry of Health of the Republic of Indonesia. (2022). Jenis dan fase penyembuhan luka. Direktorat Jendral Pelayanan Kesehatan, Kementerian Kesehatan Republik Indonesia. Accessed from; https://yankes.kemkes.go.id/view_artikel/1969/jenis-dan-fase-penyembuhan-luka
- Nieto-García, L., Carpio-Pérez, A., Moreiro-Barroso, M. T., Rubio-Gil, F. J., Ruiz-Antúnez, E., Nieto-García, A., & Alonso-Sardón, M. (2023). Is the Increase in Record of Skin Wounds in Hospitalized Patients in Internal Medicine Units a Side Effect of the COVID-19 Pandemic? *International Journal of Environmental Research and Public Health*, 20(3), 2228.
- Pareda, R., Maarisit, W., Pareta, D., & Lengkey, Y. K. (2022). Pengaruh Pemberian Getah Batang Pisang Goroho Putih (*Musa acuminata* L.) Terhadap Luka Sayat Pada Tikus Putih (*Rattus norvegicus*). *Biofarmasetikal Tropis (The Tropical Journal of Biopharmaceutical)*, 5(1), 29-34.
- Pearce, E. C. (2011). Anatomi dan fisiologi untuk paramedis. PT Gramedia Pustaka Utama. 290-297.
- Primadina, N., Basori, A., & Perdanakusuma, D. S. (2019). Proses penyembuhan luka ditinjau dari aspek mekanisme seluler dan molekuler. *Qanun Medika-Medical Journal Faculty of Medicine Muhammadiyah Surabaya*, 3(1), 31-43.
- Purnamasari, D. (2021). Pengaruh perawatan luka menggunakan natrium clorida 0, 9% terhadap penyembuhan luka pasien DM: Literature Review. *Jurnal Nurse*, 4(2).
- Tamuntuan, D. N., De Queljoe, E., & Datu, O. S. (2021). Uji Efektivitas Penyembuhan Luka Sediaan Salep Ekstrak Rumput Macan (*Lantana Camara* L) Terhadap Luka Sayat Pada Tikus Putih Jantan (*Rattus Norvegicus*). *Pharmacology*, 10(3), 1040-1049.
- Turay, F. M. (2023). Banana peel can be utilize as a promising alternative for medicinal activities (Cancer Treatment) (Doctoral dissertation, University of Sierra Leone).

Auliya Wanda Azzarin, Sugeng Mashudi*, Sulisty Andarmoyo, Fadhilah Nurul Karimah, Nuraini Khoiroton Amanah

Fakultas Ilmu Kesehatan Universitas Muhammadiyah Ponorogo
Corresponding author: *E-mail: sugengmashudi@umpo.ac.id

DOI: <https://doi.org/10.33024/minh.v7i2.227>